18 Types of Breast Cancer

- Malignant breast carcinoma is a common occurrence in postmenopausal women, usually arising from the terminal duct/lobular unit.
- Malignant breast carcinoma is most commonly discovered in the outer-quadrant of the breast due to increased amounts of dense connective tissue.
- Metastasis to the axillary lymph node is the single most important prognostic indicator.
- Risk factors include increased estrogen exposure, with increased total number of menstrual cycles, older age of first live birth, obesity, and genetic mutations in BRCA-1,2.
- Tests performed on samples of breast tissue:
  - S phase fraction above 5% is poor prognosis.
  - DNA ploidy (diploid tumor has a better prognosis than an aneuploidy tumor).
  - Overexpression of c-erbB2 (HER-2/neu, which is a human epidermal growth factor receptor) and topoisomerase II α are indicators of breast carcinoma with low survival rates.

Important Concept

Comedocarcinoma

This is a subtype of **ductal** carcinoma in situ, which is defined as a central ductal area of caseous necrosis surrounded by malignant cells.

▼Table 18–18.0 Types of Breast Cancer

Noninvasive	
Ductal carcinoma in situ (DCIS) 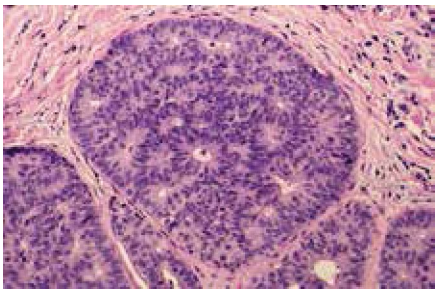	Nonpalpable patterns: cribriform (sieve-like), comedo (necrotic center)
	Commonly contain **microcalcifications;** cannot be detected by mammogram unless microcalcifications are present
	One third eventually invade
	Treated with "lumpectomy"
Lobular carcinoma in situ 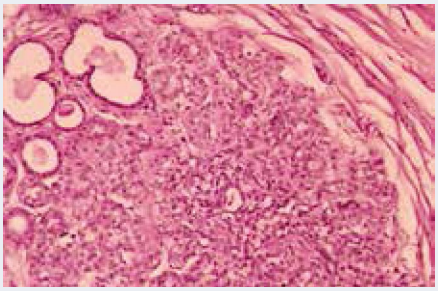	Nonpalpable; virtually always an incidental finding in a breast biopsy for other reasons; cannot be identified by mammography
	Lobules distended with bland neoplastic cells; one third eventually invade; usually **estrogen and progesterone receptor positive**
	Lobular carcinoma in situ is a precancerous lesion carrying an increased risk for invasive type of lobular carcinoma either in the ipsilateral or contralateral breast

Credits (top to bottom): Dr. Gladden Willis/Visual's Unlimited, Inc.; Custom Medical Stock Photo

© DeVry/Becker Educational Development Corp. All rights reserved.

▼Table 18–18.0 Types of Breast Cancer *(continued)*

Invasive	
Infiltrating ductal carcinoma	Stellate morphology, indurated, gray-white tumor One third have amplification of **ERBB2 oncogene**
	Gritty on cut section
	Induration caused by reactive fibroplasia (desmoplasia)
Paget disease of nipple 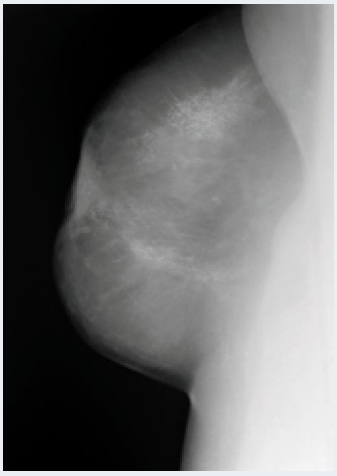	**Extension of DCIS into lactiferous ducts and skin of nipple, producing a rash with or without nipple retraction**
	Paget cells are present
	Palpable mass present in 50% to 60%
Inflammatory carcinoma	Erythematous breast with dimpling like an orange (peau d'orange) due to fixed opening of the sweat glands, which cannot expand with lymphedema
	Plugs of tumor blocking lumen of dermal lymphatics cause localized lymphedema
	Very poor prognosis
	Combination chemotherapy followed by surgery and irradiation
Medullary carcinoma	As the name implies, bulky soft tumor with large cells and a lymphoid infiltrate
	Majority are negative for estrogen and progesterone receptors
	There is, however, an association with BRCA1 mutations

Credits (top to bottom): Bolershot Photo/Science Source; Wellcome Images; B. Slaven, MD/Custom Medical Stock Photo

© DeVry/Becker Educational Development Corp. All rights reserved.

▼Table 18–18.0 Types of Breast Cancer *(continued)*

Invasive	
Invasive lobular carcinoma 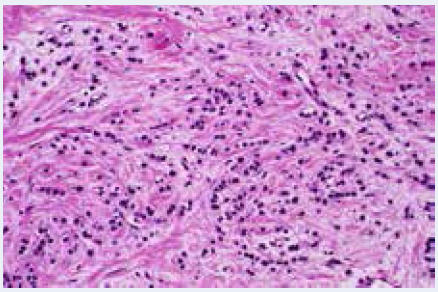	This cancer, as stated previously, may develop in the contralateral breast in a patient with lobular carcinoma in situ in 5%–10% of cases
	The neoplastic cells are arranged linearly or in concentric circles, bull's-eye appearance, in the stroma
Tubular carcinoma	These will develop in the terminal ductules with a 10% chance of developing cancer in the contralateral breast
Colloid (mucinous) carcinoma	This type is usually found in elderly women where the neoplastic cells are surrounded by extracellular mucin

Credits: Dr. Gladden Willis/Visuals Unlimited, Inc.

© DeVry/Becker Educational Development Corp. All rights reserved.